



Email comments/questions to
compendium@medimedia.com
or fax 800-556-3288

CE

Article #4 (1.5 contact hours)
Refereed Peer Review

KEY FACTS

- The etiology of progressive ethmoid hematoma remains unknown; however, progression of the hematoma occurs by repeated subcapsular hemorrhage.
- Progressive ethmoid hematomas are often extensive, involving the nasal cavity and paranasal sinuses at diagnosis.
- Surgical and conservative treatment options are available; however, prognosis for long-term resolution remains guarded to poor due to recurrence.

Progressive Ethmoid Hematoma in Horses

Kansas State University

Kelly L. Stich, DVM

Bonnie R. Rush, DVM, MS, DACVIM

Earl M. Gaughan, DVM, DACVS

ABSTRACT: Progressive ethmoid hematoma is a widely recognized disease process in horses but has an incompletely understood etiopathogenesis. The mass lesion of progressive ethmoid hematoma expands by repeated hemorrhage and is usually extensive when a diagnosis is made. Diagnostic techniques (e.g., upper airway endoscopy, radiography, computed tomography) aid in determining the extent of a progressive ethmoid hematoma. Definitive diagnosis is determined by histopathologic examination. Treatment is based on location, size, and extent of the lesion, along with consideration of economics and equipment availability. Multiple treatment options are available, including surgical resection, surgical reduction with application of cryogens or laser therapy, and intralesional formalin injection. Despite treatment, prognosis for long-term resolution remains guarded to poor due to high rates of recurrence.

Progressive ethmoid hematoma is an uncommon, nonneoplastic condition of the nasal passages and paranasal sinuses of horses. Although progressive ethmoid hematoma is a well-known clinical entity, its etiopathogenesis is incompletely understood. Modern diagnostic equipment is helpful in determining the extent of the lesions. This article provides an overview of the disease, diagnosis, and available treatments for progressive ethmoid hematoma in horses.

BACKGROUND/SIGNALMENT

The clinical and pathologic signs associated with progressive ethmoid hematoma have been available for some time as retrospective case reviews date to the 1930s.^{1,2} However, the etiopathogenesis is incompletely understood. Prevalence of progressive ethmoid hematomas in hospital populations is reported at 0.03% to 0.04% (1 in 2500 horses).^{2,3} Horses with progressive ethmoid hematomas have been reported to represent 4% of horses with disease of the nasal cavity and paranasal sinuses and 10% of horses undergoing nasal or sinus surgery.⁴

Progressive ethmoid hematomas have been reported in horses from 4 weeks to 20 years of age, with a mean of 9.9 years reported in one review.^{1,2,5} There appears to be an increased likelihood of a progressive ethmoid hematoma forming as age increases.² The prevalence among males and females is statis-

tically similar in two reports,^{2,6} yet other reports suggest more frequent occurrence in male horses.^{1,7} Speculation also exists about a possible link between female hormones and a higher incidence of bilateral disease.⁸ Progressive ethmoid hematoma has been diagnosed in Arabians, thoroughbreds, Irish hunters, quarter horses, warmbloods, Appaloosas, Tennessee walking horses, Argentinean ponies, and Belgians.^{1,2,4-6} The authors were unable to locate any reports of progressive ethmoid hematoma in standardbred horses.²

PATHOPHYSIOLOGY

Progressive ethmoid hematomas enlarge by repeated hemorrhage in the submucosa of an endoturbinete. This subsequently stretches and thickens the mucosa to form a capsule.¹⁻⁴ The well-encapsulated mass originates from the ethmoidal labyrinth within the paranasal sinuses or nasal cavity and expands to fill the cavity in which it is developing (Figure 1).¹⁻³ The progressive nature may cause local distortion and destruction of soft tissue and bone. The increases in size often produce ulceration of the mucosa covering the progressive ethmoid hematoma and result in ipsilateral epistaxis (Figure 2).¹⁻³ The blood supply supporting a progressive ethmoid hematoma usually originates from an extension of the major vessels to the ethmoid labyrinth.³ Adjacent mucosal vessels may also support a progressive ethmoid hematoma.

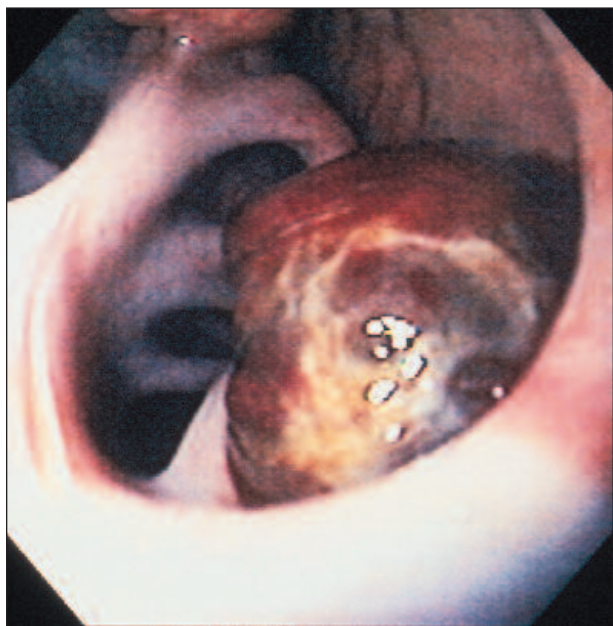


Figure 1—The endoscopic appearance of a progressive ethmoid hematoma originating in the nasal portion of the ethmoidal labyrinth.

The ethmoidal labyrinth is composed of nasal cavity and sinus components. Therefore, a progressive ethmoid hematoma can be exclusively in the nasal cavity or may extend dorsally into the conchofrontal sinus, ventrally into the sphenopalatine sinus, or into the maxillary sinuses.^{1-3,9} A progressive ethmoid hematoma can also extend directly into the dorsal or ventral ethmoidal meatus without paranasal sinus involvement.¹ It is not unusual for a progressive ethmoid hematoma to fill and obliterate the conchofrontal and caudal maxillary sinuses with only minimal to no nasal component.³ This is thought to result from the high proportion of the ethmoidal labyrinth within the paranasal sinuses. Progressive ethmoid hematomas are most commonly unilateral but may occur bilaterally (15% to 16% of cases).^{2,3} Some unilateral lesions may also enlarge and involve the contralateral nasal cavity.

CLINICAL SIGNS

The most common clinical sign associated with progressive ethmoid hematoma is mild, intermittent, unilateral epistaxis (Figure 2) due to ulceration or discontinuity of the respiratory epithelium covering the mass (Figure 3).^{1,2,4-7,10-15} Frank hemorrhage may be observed at the nares. Blood can also appear as a sanguineous component of a serous or mucopurulent nasal discharge, which can result from local destruction or pressure necrosis caused by the primary lesion.^{1,4} The discharge can become malodorous over time. Epistaxis can be spontaneous or occur during periods of exercise or breeding.^{1,2,6}

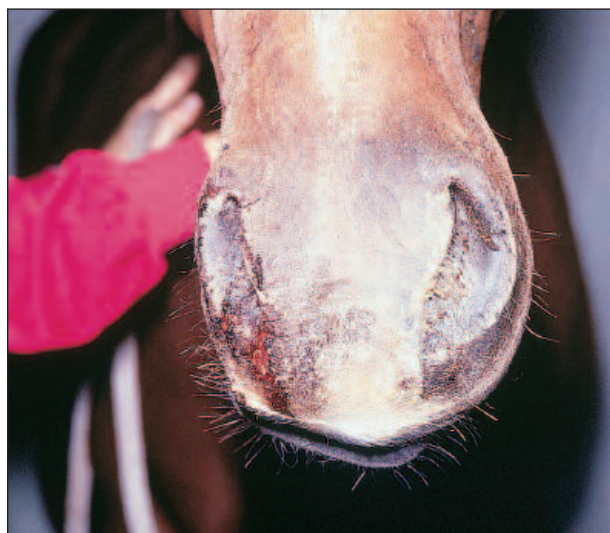

Figure 2—Low volume, unilateral epistaxis is the most common clinical sign observed with a progressive ethmoid hematoma.

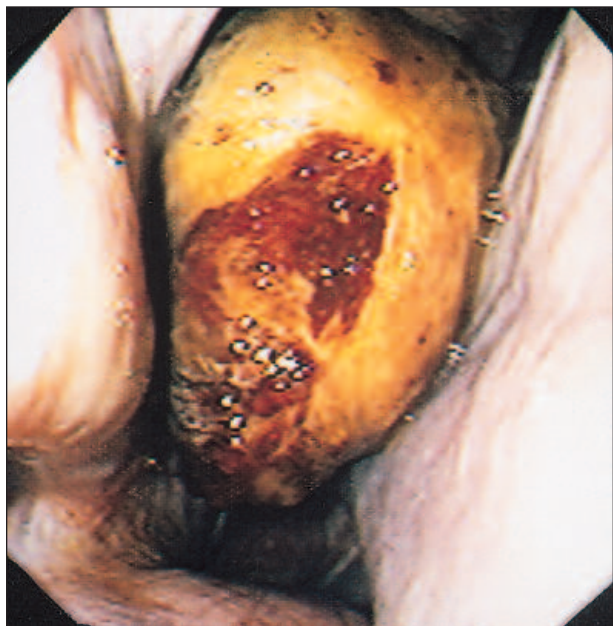

Figure 3—An endoscopic view of a progressive ethmoid hematoma that is yellow in color with superficial hemorrhage present on the capsule.

Abnormal respiratory noise can be noted in some horses with progressive ethmoid hematoma. The abnormal noise is audible in the upper airway and often loudest over the trachea.^{1,2,6,10,12–16} Progression of an ethmoid hematoma into the nasal cavity or distortion of the paranasal sinuses can cause increased turbulence of airflow, thereby creating stridor. An ethmoid hematoma can progress to fill and obstruct the nasal passage, reducing airflow through the nares and occasionally causing increased respiratory effort during exercise or even at rest.^{1,4,6,10,13,14,16}

Other clinical signs of progressive ethmoid hematoma include distortion of the facial bones,^{6–8,10,14,15} swelling over the caudal maxillary sinus,^{5,6,10} dull resonance upon percussion of the maxillary sinus,^{4,14} head shyness, and head shaking.^{1,14} If a progressive ethmoid hematoma extends into the nasopharynx, coughing, dysphagia, or excess salivation may be present.^{1,14} In one reported case, the only clinical sign observed was protrusion of the mass from the nares.¹²

Some horses affected with progressive ethmoid hematoma are normal on physical examination.² The progressive ethmoid hematoma may be found incidentally when an endoscopic examination is performed. Owners seek veterinary advice when the lesion is clinically apparent, by which time the mass may have very substantial involvement in the nasal cavity and paranasal sinuses. If a progressive ethmoid

hematoma could be identified earlier, the horse might be more readily treatable and less difficult to manage.

DIAGNOSIS

A tentative diagnosis of progressive ethmoid hematoma can be made based on history, clinical signs, upper airway endoscopic examination, and radiography. However, definitive diagnosis depends on histologic evaluation. Other imaging modalities, including computed tomography (CT) and magnetic resonance imaging (MRI), may be valuable for determining the size and location of the mass along with the extent of structural damage.

Endoscopic examination may be the most valuable tool for initial diagnosis of progressive ethmoid hematoma and may also help determine the extent of the lesion.^{4–6,10–17} The left and right nasal passages should be examined because lesions can be unilateral, with extension into the contralateral nasal cavity, or bilateral.^{1,2,7,13,14} Typical endoscopic appearance of a progressive ethmoid hematoma is a greenish-yellow to purplish-red mass that may obscure part to all of the nasal cavity.^{1,2,7} The color variations are due to the type and distribution of hemoglobin pigments (Figures 1 and 3). Progressive ethmoid hematomas have an irregular bulb-shaped rostral surface^{2,7} and can present as multiple masses or a multilobulated single mass.^{2,11,12} The endoscopically apparent aspect of a progressive ethmoid hematoma may be only a small portion of the total lesion as the rostral aspect of the mass may obscure the view of the total mass or mass origin.^{2,12} A progressive ethmoid hematoma may also expand into the opposite nasal passage, giving the appearance of bilateral involvement when in fact all of the abnormal tissue is originating from a single site. Occasionally, only a trickle of blood from the ethmoidal meatus may be observed.^{1,2} The nasal septum may appear deviated, reducing the size of the contralateral nasal passages.^{5,15}

Radiographic examination aids in determining paranasal sinus involvement, which may direct therapy.^{4,5–7,10–16} Most horses with progressive ethmoid hematoma have radiographically apparent lesions.² Radiographic studies should include lateral, dorsoventral, and oblique views. The lateral projection most consistently demonstrates the lesion. A progressive ethmoid hematoma appears as a smooth, diffuse, single or multilobulated soft tissue opacity associated with the ethmoidal labyrinth and possibly extending into the maxillary and/or conchofrontal sinuses.^{1,2} Other radiographic abnormalities may include fluid lines due to gas-fluid interfaces within the sinuses caused by the presence of blood or serosanguineous discharge.² Oblique radiographic projections

may help to demonstrate the mass. However, artifacts produced by the globe of the eye over the ethmoid bone can be confused with a progressive ethmoid hematoma mass.¹ Other radiographic abnormalities indirectly consistent with progressive ethmoid hematoma include nasal septal deviation and loss of mineral density of adjacent osseous structures. The described radiographic features are not specific to a progressive ethmoid hematoma as other disease processes of the paranasal sinuses can create the same radiographic images. Therefore, radiography alone should not be used to diagnose progressive ethmoid hematomas. Positive-contrast radiography can help provide a more complete sinus evaluation.^{2,18}

Computed tomography and MRI can improve diagnostic evaluation of the nasal and sinus regions. CT can aid in the determination of location, size, and extent of a progressive ethmoid hematoma. It can also help delineate the involvement of other structures.^{1,5,14} Cross-sectional views of the skull can eliminate potential superimposition of the paranasal sinuses over the nasal cavity that complicates other radiographic studies.^{1,19} CT image quality is superior in differentiating various tissue densities. This allows more detailed localization, which in turn, can direct appropriate treatment selection.¹⁹ The greatest limitation of CT and MRI is availability.

Although a tentative diagnosis can be based on history, clinical signs, and endoscopic examination, definitive diagnosis can be provided only with histologic examination. Biopsy samples from a progressive ethmoid hematoma located in the nasal cavity may be obtained via endoscopic guidance.^{2,12} A progressive ethmoid hematoma located within the paranasal sinuses can be sampled using an arthroscope

and biopsy instrument introduced through trephine holes in the paranasal sinuses.¹⁷ The distinctive histopathologic features of a progressive ethmoid hematoma are the result of repeated local hemorrhage, subsequent breakdown of hemoglobin, and organization of the breakdown products.^{2,7,9,14} The outer membrane consists of variably intact respiratory epithelium characterized as flattened, columnar, cuboidal, ciliated epithelium containing glands and/or occasionally characterized as stratified squamous epithelium.^{2,9} An irregular zone of submucosal fibrous tissue with varied fibroplasia (from loose connective tissue and fibrin containing few fibroblasts to a dense, fibrous connective tissue stroma) is typical of progressive ethmoid hematoma (Figure 4).^{2,9} The central aspect of the mass usually consists of old and recent hemorrhage with variable inflammatory infiltrates of hemosiderin-laden macrophages, plasma cells, lymphocytes, and less commonly, neutrophils and eosinophils (Figure 5). Numerous, irregularly shaped, multinucleated giant cells are present in most cases.^{2,9} Progressive ethmoid hematoma is not likely a neoplastic process as it does not demonstrate uncontrolled, progressive cell multiplication, which is a hallmark of neoplasia.²

DIAGNOSTIC DIFFERENTIALS

When considering progressive ethmoid hematoma, the diagnostic differentials should include conditions that result in persistent or intermittent epistaxis or blood-tinged nasal discharge. These conditions include guttural pouch mycosis, skull fracture, nasal trauma, foreign body, ulcerative or fungal rhinitis, ethmoidal neoplasia, paranasal sinus cyst, pulmonary abscess, paranasal sinus infection, pulmonary neoplasia,

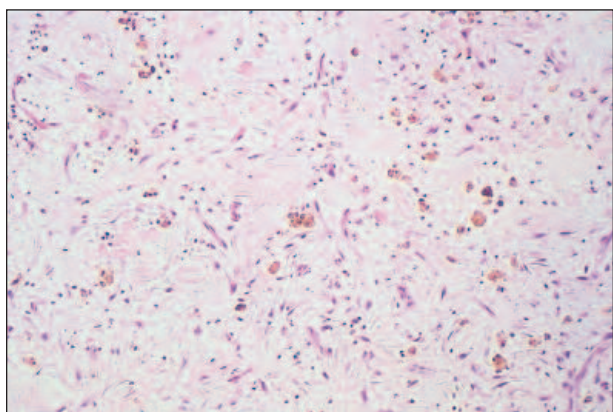


Figure 4—The histopathologic appearance of a progressive ethmoid hematoma demonstrating an irregular zone of submucosal fibrous tissue consisting of fibroblasts, inflammatory infiltrate, and hemosiderin-laden macrophages.

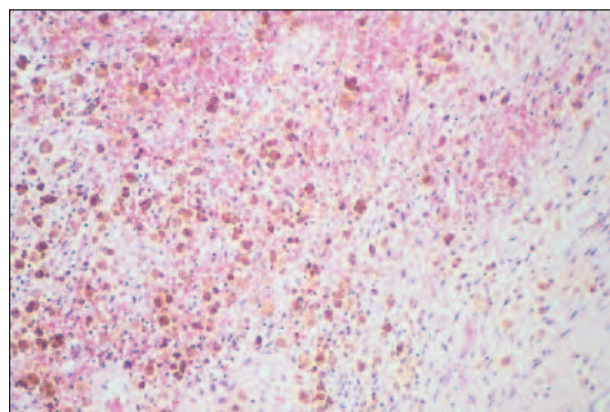


Figure 5—The histopathologic appearance of a progressive ethmoid hematoma demonstrating evidence of old and recent hemorrhage. This is characterized by the presence of red blood cells and hemosiderin-laden macrophages.

infectious pleuropneumonia, and exercise-induced pulmonary hemorrhage.^{1,2} The history, physical examination findings, and upper respiratory endoscopic examination can differentiate the majority of these disease processes. The distinctive endoscopic appearance of progressive ethmoid hematoma generally allows an accurate tentative diagnosis. However, there are several nasal masses that have similar endoscopic appearance, including nasal polyps, ulcerative or mycotic rhinitis, neoplasia, and nasal trauma.² Therefore, definitive diagnosis via biopsy is recommended.

TREATMENT

Early recognition and treatment of a horse with progressive ethmoid hematoma can produce the best outcome. The prognosis for athletic performance and survival without treatment is unfavorable as the mass will progressively enlarge and eventually obstruct the nasal passages and distort the upper airway.^{1,4,6,11} Techniques that have been described for treatment of horses with progressive ethmoid hematoma include surgical excision through a frontonasal bone flap, surgical excision with cryotherapy of the base of the mass, cryotherapy of the mass without surgical excision, transendoscopic neodymium:yttrium-aluminum-garnet (Nd:YAG) laser photoablation, laser excision through a frontomaxillary bone flap, and transendoscopic intraleisional injection of 10% formalin.^{1,3-8,10-16,20-23} The extent and location of the lesion may determine which therapy or therapies are used. The prognosis for long-term resolution even with appropriate intervention is considered guarded to poor.^{4,6,11}

Surgical Resection/Reduction

Surgical excision of a progressive ethmoid hematoma with the horse under general anesthesia has been the treatment of choice for many years.^{1,7,13} The appropriate surgical approach depends on the size and location of the lesion. A frontonasal bone flap is the recommended approach.^{1,3,6,7,10,11,13-16,20} However, a maxillary bone flap may be required as an additional approach. Raising a frontonasal bone flap allows versatility in tissue manipulation, especially if there is involvement of both the nasal cavity and paranasal sinuses. Using a frontonasal bone flap allows visualization of the frontal sinus and medial wall of the dorsal conchal sinus. Perforation of the medial wall exposes the nasal portion of the ethmoidal labyrinth. This allows surgical resection of a progressive ethmoid hematoma arising from the nasal or sinus area of the ethmoidal labyrinth.^{2,3,7} A progressive ethmoid hematoma can be carefully dissected from surrounding tissue and then excised at the base or removed with rapid sequential

excisions of portions of the mass.^{3,7} The ethmoid labyrinth is commonly destroyed during surgical excision, but this is of slight consequence as the ethmoid labyrinth readily regenerates.³

Due to voluminous hemorrhage, the nasal cavity often requires firm packing with a continuous strip of gauze for hemostasis. The gauze can be exited through the nasal passage or through a small trephine hole into the conchofrontal sinus, remote from or within the cutaneous and osseous incisions.^{1,3,6,7,10,11,16} The gauze pack should be removed 48 to 72 hours after surgery. If substantial hemorrhage is encountered during the removal process, the nasal cavity should be repacked and this pack should be left in place for 12 to 24 hours. Perioperative systemic antibiotics and NSAID therapy should be administered.^{1,6,7,10,11,15,16} Lavage of the paranasal sinuses has been suggested to eliminate accumulated exudate, blood clots, and tissue debris after the packing is removed.^{1,11} After surgery, horses typically have a serosanguineous to mucoid nasal discharge for approximately 2 to 3 weeks. Some reported cases have had nasal discharge for up to 1 year.¹¹ Horses should be restricted to stall rest with hand walking for 3 weeks after surgery.^{1,6}

Intraoperative hemorrhage is the most common complication of surgical excision. One report documented an average blood loss of 4.5 L with a single horse losing 15 L in 5 minutes.^{3,6} Prior to surgery, a coagulation profile and cross-match to identify a suitable blood donor are recommended. In instances of large masses, 4 to 8 L of blood should be readily available for transfusion.^{1,3,6,7,10,11} Isotonic fluids should be administered intravenously before, during, and after surgery to alleviate hypotension associated with blood loss.^{1,7} The amount of fluids administered is based on physical examination findings, complete blood cell counts, electrolyte profile results, and performance while under anesthesia. Other techniques that have been described to address intraoperative hemorrhage include bilateral temporary carotid artery occlusion, roll gauze packing of the sinuses or nasal cavity and/or vascular clamps, photocoagulation with Nd:YAG laser, electrocautery, cold saline sponges, epinephrine-soaked sponges, and cryotherapy techniques applied to the base of the mass.^{1,3,6,7,10,11,24}

The second most common complication of surgical treatment of progressive ethmoid hematoma is respiratory distress after endotracheal tube removal.^{6,7,10,11,15,16} Respiratory distress occurs when significant postsurgical nasopharyngeal edema is present. Preparations should be made to perform a temporary tracheostomy on all cases. Horses with

bilateral disease should receive a temporary tracheostomy prior to surgery because both nasal passages will be packed with gauze after surgery.^{6,7,10,11} Other complications include wound dehiscence,⁶ facial deformity,¹⁶ facial bone sequestration,¹¹ suture periostitis,¹¹ localized wound infection,¹ exophthalmus,¹⁶ blindness, encephalitis,^{4,11} colic,¹⁰ fever, diarrhea,^{6,10} and fungal infection.¹¹

The recurrence of progressive ethmoid hematoma after surgical excision is relatively high (30% to 60%).^{1,3,6,10,11} The recurrence varies among surgeons, with the most important factor being the degree of removal.³ Various means have been used to determine recurrence rates, with most based on clinical signs and no follow-up endoscopic examination.^{3,6,8,10,11} The actual recurrence rate of progressive ethmoid hematoma may be higher than the published reports as some lesions may take a prolonged period of time to regrow before clinical signs develop.^{8,12}

Cryosurgery

Cryosurgery using liquid nitrogen as the cryogen can be performed through the nasal passage or via bone flap exposure guided by endoscopy or arthroscopy.^{1,3,7,13,14,20} The recommended technique involves sequential freezing of small portions of the progressive ethmoid hematoma with surgical removal of the frozen tissue until the base can be visualized and frozen. Cryosurgery requires adequate tissue exposure and a blood-free surgical field, as the therapy is ineffective when profuse hemorrhaging is present.^{1,3,7,13} Cryogens can be applied with the horse standing and sedated using a probe or spray technique.⁷ Cryogen application to the base of a progressive ethmoid hematoma can precede surgical excision.^{3,7} A lower incidence of recurrence has been reported for horses treated with a combination of surgical debulking and cryotherapy than with cryosurgery alone.^{1,3,7,20} However, a study of nine horses reported no difference in recurrence among horses treated with cryotherapy and surgical removal compared with other methods of treatment.⁶ Hemorrhage control is an advantage of cryotherapy as minimal hemorrhaging occurs in frozen tissue.^{1,3,7} The greatest reported risk of cryosurgical removal of progressive ethmoid hematoma is damage to the cribriform plate and subsequent brain damage.^{3,7} Therefore, judicious use of cryogens is encouraged with each freeze reaching -10°C and the depth of freeze controlled by placement of thermocouples in the ethmoidal labyrinth.¹ The use of cryogen therapy can be limited by difficulty in obtaining access to the progressive ethmoid hematoma, difficulty in placing thermocouples to control the depth of freezing, and requirement of a large liquid nitrogen unit.^{1,3,7}

Transendoscopic Nd:YAG Laser Excision

Surgical lasers can incise, coagulate, photoablate, and weld tissues. The greatest advantage of surgical lasers for removal of progressive ethmoid hematoma is increased accuracy of lesional excision, reduced surgical morbidity and convalescent time, and improved overall outcome of treatment.^{1,3,7,8,13,14,22} Surgical lasers are reported to reduce the amount of hemorrhage.^{1,3} The Nd:YAG laser delivers energy through a long, small diameter, flexible, optical fiber that can be passed through the biopsy channel of an endoscope. Contact technique involves use of a sculptured fiber or a synthetic sapphire tip attached to the end of the optical fiber to deliver 15 to 30 W of laser energy directly to the tissue, causing less thermal damage to surrounding tissues than the noncontact technique.^{8,21} Noncontact technique involves positioning the tip of the optical fiber 5 to 10 mm from the lesion and using high powers of 50 to 100 W of laser energy to cause massive photovaporization and coagulation of tissue.⁸ The contact technique is recommended when a large progressive ethmoid hematoma with extensive paranasal sinus involvement is treated through a bone flap.⁸ The noncontact technique can be used when a small progressive ethmoid hematoma is located in the nasal cavity and benefit can be gained from the forward and lateral tumbling of laser radiation, causing latent thermal damage and sloughing of more tissue.⁸

Nd:YAG laser resection of progressive ethmoid hematoma can be performed in the standing, sedated horse.^{1,3,8} Multiple treatments may be required to completely ablate a progressive ethmoid hematoma.⁸ The number of treatments required is likely variable as reported case numbers are insufficient to establish an average. A 7-day interval is recommended between treatments.¹ Depth, narrowness, and complexity of the ethmoid labyrinth makes complete excision or photoablation of the origin of a progressive ethmoid hematoma difficult when using only an endoscopic approach.^{3,8} To assist complete excision, paranasal sinuses can be accessed via a trephine hole, with the endoscope and laser advanced to reach aspects of a mass inaccessible via the nasal passage. The ethmoid labyrinth architecture can be altered after laser ablation and will appear different on follow-up endoscopy. Perioperative antibiotics and NSAID therapy is recommended.⁸ Although decreased hemorrhaging is reported in horses treated with the Nd:YAG laser, packing of the nasal cavity after resection is recommended.^{1,8} Horses should be rested for 30 days and slowly reintroduced to previous exercise.⁸

The most frequent complication after Nd:YAG laser resection of a progressive ethmoid hematoma is

respiratory distress due to substantial inflammation within the nasal cavity and pharynx after laser application, with 9 of 20 cases in one study requiring a temporary tracheostomy.⁸ Hemorrhage has also been commonly noted and can decrease visibility of the surgical field. Use of the Nd:YAG laser is reported to decrease the amount of hemorrhage with an average of 2 to 3 L lost per horse during a single treatment.^{1,3,8} No horses treated with the Nd:YAG laser have been reported to require intraoperative blood transfusion.^{1,3,8,21} Other complications of Nd:YAG laser ablation include meningoencephalitis, respiratory noise due to nasal and septal thickening, and bacterial infection of the surgical site.⁸ Recurrence rates of progressive ethmoid hematoma after Nd:YAG laser treatment are reported to be 20% to 22%.⁸

Intralesional Formalin

Formalin has been used to treat humans affected with radiation-induced hemorrhagic cystitis or proctitis.²² It has also been used to involute chronically infected quarters of dairy cattle and to ablate the parotid salivary gland of horses.^{23,25} Formalin desiccates and coagulates tissue by hydrolyzing protein.^{12,15} Formalin (a 4% solution of formaldehyde) has been successfully used to treat horses with progressive ethmoid hematoma.^{4,12,14,15,23} Three administration techniques have been described using endoscopic visualization and intralesional injection:

- An 8-Fr polypropylene urinary catheter can be modified by placing an 18-gauge needle on the end. This injection apparatus is placed in an artificial insemination pipette and passed dorsal to the endoscope.⁴
- A firm plastic catheter can be modified by placing an 18-gauge needle on the end. This can then be passed through the biopsy channel of an endoscope.⁴
- A polypropylene catheter with a retractable, swaged-on, 23-gauge needle can be passed through the biopsy channel of an endoscope and used for injection.^{12,15}

The preferred technique is to use an injection apparatus that can be readily passed through the biopsy channel of an endoscope for reliable visualization and placement of the needle (Figure 6).^{4,12,15,23} The reported volume and frequency of injection varies from 1 to 100 ml injected every 4 days to every 6 months.^{4,12,15} However, the recommendation of injecting a volume that distends the progressive ethmoid hematoma and begins to leak from the site of injection is consistent

with all reports. Intralesional injections are probably best performed at least 2 weeks apart for desired tissue sloughing between injections (Figure 7). Injection periods should be frequent (every 2 to 4 weeks) and continued until the mass has apparently resolved or can no longer be injected.⁴ Formalin can be injected in a standing, sedated horse with passage of the endoscope into the nasal cavity. A progressive ethmoid hematoma in the paranasal sinus may require a trephine hole for direct intralesional formalin administration.⁴ Systemic NSAID therapy should be administered prior to intralesional formalin injection.^{4,12,15,23}

The results of intralesional formalin administration have been favorable. Most horses have reportedly experienced a substantial decrease in size of the progressive ethmoid hematoma and remission of clinical signs. Some lesions have remained inactive with no clinical signs present for 9 to 42 months.^{4,12,23} Recurrence can occur, yet reported case numbers are not sufficient to establish an expected rate of recurrence. Frequent endoscopic examinations are recommended to assess the progressive ethmoid hematoma and determine future treatment requirements. Formalin injection can be performed on an outpatient basis, is inexpensive, and requires minimal equipment. A short convalescent time is experienced, and an affected horse can continue athletic activity between treatments.^{4,12,23}

Although intralesional formalin injection has demonstrated great promise for treatment of progressive ethmoid hematoma, it is not without

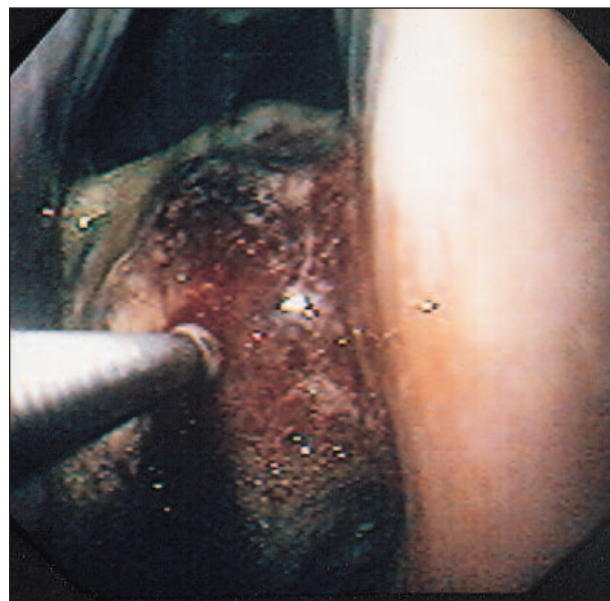


Figure 6—The endoscopic appearance of a formalin injection into a progressive ethmoid hematoma.

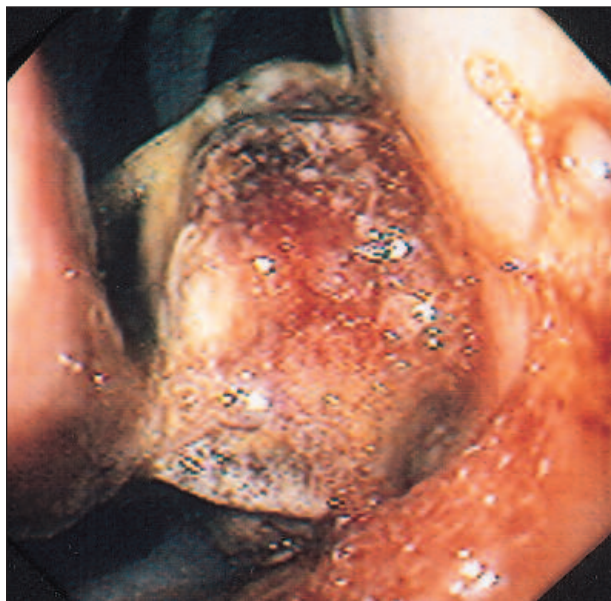

Figure 7A—Before formalin treatment

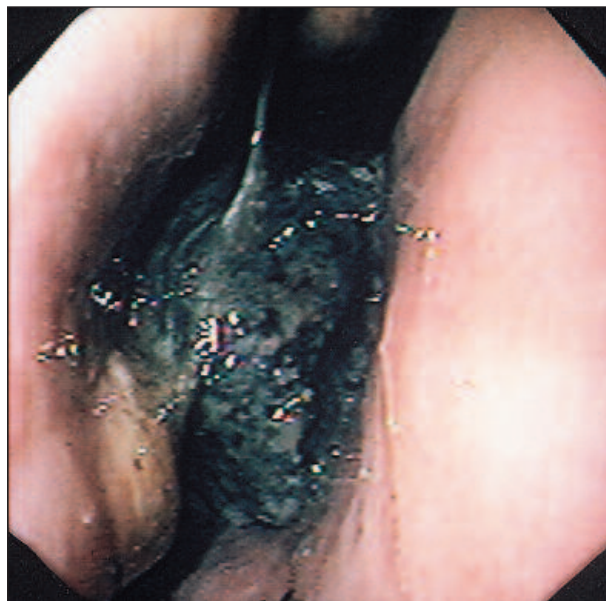

Figure 7B—Two weeks after formalin treatment

Figure 7—(A) An endoscopic view of a progressive ethmoid hematoma prior to injection with 10% formalin. **(B)** Two weeks after formalin injection, the progressive ethmoid hematoma has decreased in size and has a necrotic appearance.

complications. The most frequently encountered complication is copious nasal discharge for 5 to 7 days after injection.⁴ One horse with a previous history of laminitis had mild laminitic episodes after three intralesional formalin treatments. Clinical signs of laminitis resolved within 24 hours of treatment with NSAIDs, and no untoward, long-term adverse effects were observed.¹² Intravenous formalin has been associated with restlessness, lacrimation, salivation, elevation of the tail, increased gastrointestinal motility, tenesmus, defecation, and signs of abdominal pain.⁴ None of these signs have been described in horses after intralesional formalin treatment of progressive ethmoid hematomas.^{4,12} Severe neurologic complications, stupor, and death after a single intralesional injection of formalin into a progressive ethmoid hematoma have been reported in one horse.¹⁵ The cribriform plate had been damaged by the progressive ethmoid hematoma, and the formalin reached the frontal lobes of the brain. The loss of integrity of the cribriform plate was not observed on endoscopic or radiographic examination. It was in the authors' opinion that a CT scan or MRI may be essential in determining the extent of excessively large progressive hematomas to avoid this complication of formalin treatment and potentially other treatment modalities as well.¹⁵ Careful case selection for formalin therapy and specific imaging assessment are advised prior to injection.

SUMMARY

The development of a management plan for progressive ethmoid hematoma requires consideration of the intended use of the horse, equipment, facilities, personnel available, and the wishes of the owner. Various treatments are available, and some can be used in combination. A guarded to poor prognosis is appropriate due to high recurrence despite treatment. However, with currently available surgical and medical therapy, progressive ethmoid hematoma is not life threatening and many affected horses have been able to perform at their previous level of competition. Repeated endoscopic examinations should be performed at 3- to 6-month intervals after treatment of horses for progressive ethmoid hematoma for at least 5 years to monitor for recurrence.

REFERENCES

1. Nickels FA: Ethmoid hematoma, in White NA, Moore JN (eds): *Current Techniques in Equine Surgery and Lameness*, ed 2. Philadelphia, WB Saunders Co, 1998, pp 127–130.
2. Bell BLT, Baker GJ, Foreman JH: Progressive ethmoid hematoma: Background, clinical signs, and diagnosis. *Compend Contin Educ Pract Vet* 15(8):1101–1110, 1993.
3. Bell BLT, Baker GJ, Foreman JH: Progressive ethmoid hematoma: Characteristics, cause, and treatment. *Compend Contin Educ Pract Vet* 15(10):1391–1401, 1993.
4. Marriott MR, Dart AJ, Hodgson DR: Treatment of progressive ethmoidal haematoma using intralesional injections of formalin in three horses. *Aust Vet J* 77(6):371–373, 1999.

5. Colbourne CM, Rosenstein DS, Steficek BA, et al: Surgical treatment of progressive ethmoidal hematoma aided by computed tomography in a foal. *JAVMA* 211(3):335–338, 1997.
6. Specht TE, Colahan PT, Nixon AJ, et al: Ethmoidal hematoma in nine horses. *JAVMA* 197(5):613–616, 1990.
7. Meagher DM: Ethmoid hematoma, in White NA, Moore JN (eds): *Current Practice of Equine Surgery*. Philadelphia, JB Lippincott Co, 1990, pp 227–230.
8. Rothaug PG, Tulleners EP: Neodymium:yttrium-aluminum-garnet laser-assisted excision of progressive ethmoid hematomas in horses: 20 cases (1986–1996). *JAVMA* 214(7):1037–1041, 1999.
9. Tremaine WH, Clarke CJ, Dixon PM: Histopathological findings in equine sinonasal disorders. *Equine Vet J* 31(4):296–303, 1999.
10. Laing JA, Hutchins DR: Progressive ethmoidal haematoma in horses. *Aust Vet J* 69(3):57–58, 1992.
11. Greet TRC: Outcome of treatment in 23 horses with progressive ethmoidal haematoma. *Equine Vet J* 24(6):468–471, 1992.
12. Schumacher J, Yarbrough T, Pascoe J, et al: Transendoscopic chemical ablation of progressive ethmoidal hematomas in standing horses. *Vet Surg* 27(3):175–181, 1998.
13. Embertson RM: Upper airway conditions in older horses, broodmares, and stallions. *Vet Clin North Am Equine Pract* 7(1):149–150, 1991.
14. Pascoe JR: Ethmoid hematoma, in Smith BP (ed): *Large Animal Internal Medicine*, ed 2. St. Louis, MO, Mosby, 1996, pp 618–620.
15. Frees KE, Gaughan EM, Lillich JD, et al: Severe complication after intralesional formalin treatment of progressive ethmoidal hematoma in a horse. *JAVMA*, submitted for publication, February 2001.
16. Behrens E: Ethmoid hematoma in a stallion. *Equine Pract* 10(3):24–27, 1988.
17. Ruggles AJ, Ross MW, Freeman DE: Endoscopic examination of normal paranasal sinuses in horses. *Vet Surg* 20(6):418–423, 1991.
18. Behrens E, Schumacher J, Morris E: Contrast paranasal sinusography for evaluation of disease of the paranasal sinuses of five horses. *Vet Radiol* 32(3):105–109, 1991.
19. Tietje S, Becker M, Bockenhoff G: Computed tomographic evaluation of head diseases in the horse: 15 cases. *Equine Vet J* 28(2):98–105, 1996.
20. Meagher DM: The elevation and surgical treatment of ethmoid hematomas in the horse. *Vet Surg* 15:128, 1986.
21. Sullins KE: Standing endoscopic electrosurgery. *Vet Clin North Am Equine Pract* 7(3):571–581, 1991.
22. Myers JA, Mall J, Doolas A, et al: Absorption kinetics of rectal formalin instillation. *World J Surg* 21(8):886–889, 1997.
23. Schumacher J, Honnas C, Yarbrough T, et al: Ablation of progressive ethmoidal hematomas of horses by intralesional injection of formaldehyde solution. *Proc Am Assoc Equine Pract* 43:244–245, 1997.
24. Wyn-Jones G, Jones RS, Church S: Temporary bilateral carotid artery occlusion as an aid to nasal surgery in the horse. *Equine Vet J* 18(2):125–128, 1986.
25. Schmotzer WB, Hultgren BD, Huber MJ, et al: Chemical involution of the equine parotid salivary gland. *Vet Surg* 20(2):128–132, 1991.

ARTICLE #4 CE TEST

The article you have read qualifies for 1.5 contact hours of Continuing Education Credit from the Auburn University College of Veterinary Medicine. *Choose the best answer* to each of the following questions; then mark your answers on the postage-paid envelope inserted in *Compendium*.

1. Definitive diagnosis of progressive ethmoid hematoma in horses is made by
 - a. endoscopic examination.
 - b. history and clinical examination.
 - c. CT.
 - d. histopathologic examination.
2. What is the prognosis for long-term resolution of progressive ethmoid hematoma?
 - a. grave no matter what treatment is performed
 - b. good if treated with intralesional formalin
 - c. guarded to poor no matter what treatment is performed
 - d. good if treated with surgical excision and cryotherapy of the base
3. In what breed have there been no reports of progressive ethmoid hematoma?
 - a. warmblood
 - b. Arabian
 - c. Tennessee walking horse
 - d. standardbred
4. What causes the color variations of the progressive ethmoid hematoma when viewed through a video endoscope?
 - a. age of the lesion
 - b. fibrosis of the mass
 - c. type and distribution of hemoglobin pigments
 - d. none of the above
5. What is the most common clinical sign observed in horses with progressive ethmoid hematoma?
 - a. coughing
 - b. epistaxis
 - c. head pressing
 - d. respiratory distress
6. Which survey radiographic view most consistently demonstrates the lesion associated with progressive ethmoid hematoma?
 - a. dorsoventral
 - b. oblique
 - c. lateral
 - d. none of the above

(continues on page 1120)

Ethmoid Hematoma *(continued from page 1103)*

7. Diagnostic differentials after visualization of the mass lesion with the video endoscope should include all of the following except?
 - a. pulmonary neoplasia
 - b. nasal trauma
 - c. nasal neoplasia
 - d. mycotic rhinitis
8. What is the most substantial complication after surgical excision of a progressive ethmoid hematoma?
 - a. facial deformity
 - b. respiratory distress
 - c. wound dehiscence
 - d. hemorrhage
9. Formalin (10%) treatment for progressive ethmoid hematoma in the horse is administered via which route?
 - a. intralesional injection
 - b. intravenous injection
 - c. intramuscular injection
 - d. a nasogastric tube placed in the stomach
10. To monitor for recurrence after treatment of a progressive ethmoid hematoma, repeat endoscopic examinations should be performed at _____ intervals for _____.
 - a. 2-week; 2 years
 - b. 1-month; 1 year
 - c. 3- to 6-month; 5 years
 - d. 1-year; 10 years