

## Compendium

# Equine Recurrent Uveitis: Classification, Etiology, and Pathogenesis

Amanda Curling, DVM

**Abstract:** Equine recurrent uveitis is a cyclical disease that affects the eye and often leads to high management costs and unfavorable results, such as blindness. Research has improved understanding of the roles of various etiologies, especially leptospirosis, in initiating and perpetuating the pathogenesis of equine recurrent uveitis. Research has also led to the discovery that specific breeds and horses with specific coat color patterns may be predisposed to developing recurrent uveitis.

**For more information, please see companion article, "Equine Recurrent Uveitis: Treatment."**

Equine recurrent uveitis is a spontaneous disease affecting up to 25% of horses and is the leading cause of blindness in horses in the United States.<sup>1,2</sup> Commonly referred to as periodic ophthalmia or moon blindness, equine recurrent uveitis affects the eye in a repetitive, cyclical manner. Because of its unrelenting nature and increasing severity with each event, equine recurrent uveitis leads to permanent blindness in more than half of affected horses, decreasing their economic and practical value.<sup>3</sup> There are more than 9.2 million horses in the United States, and the US equine industry has an annual worth of over \$100 billion (for more information, visit the American Horse Council Web site). With an estimated 10% to 25% of these horses having ocular changes due to uveitis, the financial and emotional effects of uveitis on the equine industry are profound.<sup>4</sup>

### Classification of Equine Uveitis

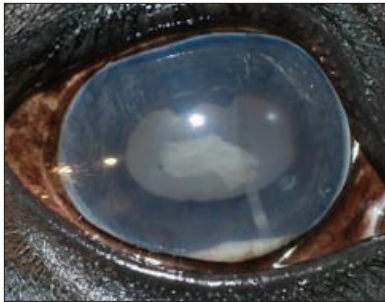Recurrent uveitis is commonly classified by stage (acute, quiescent, or chronic end-stage), and two major clinical appearances are noted. Classic equine recurrent uveitis, the most common form, is recognized by an acute inflammatory phase (blepharospasm, epiphora, corneal edema, miosis, conjunctival hyperemia, and aqueous flare), followed by periods of quiescence (**FIGURE 1; FIGURE 2**). Each cycle becomes increasingly severe, leading to chronic end-stage uveitis, which is characterized by cataracts, synechiae, phthisis bulbi, and, eventually, vision loss<sup>2,5</sup> (**FIGURE 3; FIGURE 4**). Insidious equine recurrent uveitis is usually less clinically severe than the classic form. Inflammation is low grade, never completely resolves, and slowly progresses to chronic recurrent uveitis. Overt ocular discomfort is unusual. This form is not recognized until the following changes develop: vitreal opacity, retinal degeneration and detachment, cataract formation, and blindness. This form commonly affects Draft breeds and Appaloosas.<sup>5</sup>

Uveitis can also be classified based on anatomic location. Anterior uveitis affects the iris, ciliary body, and anterior chamber. Posterior uveitis affects the retina, choroid, and vitreous. Panuveitis is inflammation of the anterior and posterior segments of the eye.

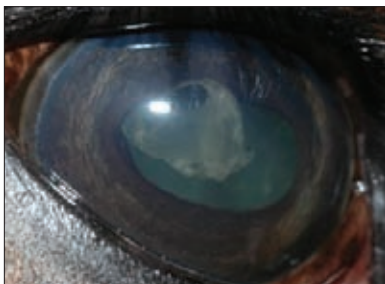
### Etiology

Equine recurrent uveitis was thought to be a type III immune complex hypersensitivity reaction, but it is now understood that cell-mediated immunity plays an important role in this disease.<sup>6</sup> The uvea develops lymphoid nodules that act as an accessory lymph node within the eye. Immunologic memory cells have been found within the eye, and inflammation recurs with each challenge by an immunogen. The inflammation activates T cells in the lymphocytic nodules, and the T cells generate a local inflammatory response or a delayed hypersensitivity reaction within the uvea.<sup>1,7,8</sup> B cells are found in smaller numbers, suggesting intraocular immunoglobulin production and a humoral immune response during equine recurrent uveitis.<sup>1</sup> Damage to the blood-ocular barrier activates proinflammatory interferon- $\gamma$ , interleukin (IL)-2, and a low amount of IL-4, which recruits T cells.<sup>6</sup> These mediators amplify the local immune response by activating and recruiting non-antigen-specific inflammatory cells to the site of inflammation. In eyes with uveitis, increased expression of major histocompatibility complex (MHC) class II antigen has been found, which is consistent with the predominance of T cells.<sup>6</sup> This complex displays antigens on an antigen-presenting cell (macrophage) to T cells by binding to the CD4<sup>+</sup> receptor on the T cell. This coordinates the killing of pathogens and infected or malfunctioning cells. T cells and MHC class II antigen are increased even in uveitic eyes that are not showing clinical signs.<sup>9</sup> These changes indicate an enhanced immune response even in apparently noninflamed eyes.

It is now understood that uveitis can be caused by many factors that disrupt normal ocular structure and function. Bacteria, viruses,




**FIGURE 1.** Acute changes characterized by corneal edema and aqueous flare with fibrin in the anterior chamber. Note the hypopyon (leukocytic exudate) settling on the ventral floor of the anterior chamber. (Courtesy of Dr. Richard McMullen, North Carolina State University Ophthalmology Service)



**FIGURE 2.** Fibrin in the anterior chamber. (Courtesy of Dr. Richard McMullen, North Carolina State University Ophthalmology Service)



**FIGURE 3.** Chronic changes characterized by cataract formation and posterior synechia. (Courtesy of Dr. Richard McMullen, North Carolina State University Ophthalmology Service)



**FIGURE 4.** Chronic changes indicated by corpora nigra degeneration and vesicular cataract formation. (Courtesy of Dr. Richard McMullen, North Carolina State University Ophthalmology Service)

parasites, trauma, and systemic disease can damage the blood-ocular barrier, allowing leakage of cells into the aqueous, vitreous, and subretinal spaces, resulting in clinically detectable uveitis.<sup>4</sup>

Viral agents associated with uveitis include influenza virus, equine herpesviruses 1 and 4, equine arteritis virus, equine infectious anemia virus, and rotavirus.<sup>10</sup> Parasites associated with uveitis include *Onchocerca cervicalis* and *Toxoplasma gondii*, both of which release large quantities of antigens within the eye, causing an immune reaction and inciting uveitis.<sup>3,4</sup> Systemic diseases caused by bacteria such as *Streptococcus equi*, *Escherichia coli*, and *Rhodococcus equi* have also led to the development of uveitis. These bacteria form microabscesses in the eye via embolization through the choriocapillaris, iris, or ciliary capillaries. After endothelial cell membrane phospholipid damage, chemical mediators of inflammation are released along with bacterial and leukocytic toxins, further damaging eye tissue and causing uveitis.<sup>4</sup>

Although several bacterial causes of uveitis exist, leptospiral infection is thought to be the most prevalent and significant. Pathogenic species in horses include *Leptospira interrogans* serovars *australis*, *bratislava*, *canicola*, *icterohaemorrhagiae*, and *pomona*; *Leptospira kirschneri* serogroup Autumnalis and serovar *grippotyphosa*; and *Leptospira borgpetersenii* serovars *ballum* and *sejroe*.<sup>11</sup> Acute *Leptospira* infection and active leptospiremia often go

unrecognized in horses because of the mild nature of this infection. Acute clinical signs are rare, but inappetence, fever, icterus, and abortion have been reported.<sup>12</sup> Uveitis often develops several months or years after initial infection, making it difficult to determine whether leptospiral infection was the cause. Serologic evidence of leptospiral infection is much more common than the incidence of uveitis, indicating that serology is unreliable for diagnosing leptospirosis as the cause of uveitis; many clinically normal horses have positive titers that can remain high for many years without clinical disease.<sup>13</sup> However, it has been demonstrated that seropositive horses are 13.2 times more likely to develop uveitis compared with horses with negative titers.<sup>14,15</sup>

Leptospiral serovars have been isolated from ocular fluids of horses with uveitis, and this is more likely to be diagnostic than serovars found in serum.<sup>13,16,17</sup> For several decades, demonstration of aqueous antibody titers and, more recently, vitreal titers against leptospiral organisms (specifically *L. interrogans* serovar *pomona* in the United States and *L. kirschneri* serovar *grippotyphosa* in Europe) using the microscopic agglutination test has been the diagnostic standard for leptospiral-induced uveitis.<sup>14,18</sup> It has been suggested that when intraocular titers exceed those of serum, leptospiral infection is in the acute phase or has remained persistent.<sup>19</sup> It was proved that intraocular antibodies are a product of not only leakage from a break in the blood-ocular barrier due to inflammation but also intraocular synthesis of antibodies (e.g., the intraocular antibody concentration can exceed that in the peripheral blood).<sup>14</sup> Electron microscopy has been used to ultrastructurally visualize leptospire within vitreal samples.<sup>18</sup> Bacterial culture has been used to grow *Leptospira* spp, and polymerase chain reaction testing has been used to detect the 16S-rDNA gene sequence of *L. interrogans*.<sup>18</sup>

### Pathogenesis

After the initial episode of uveitis, clinical signs are thought to recur due to immunologic mechanisms regardless of the presence of the inciting cause.<sup>20</sup> The exact mechanism is unknown, but several theories exist. The infectious agent or antigen could be incorporated into the uveal tract or vitreous after the initial episode, and its continued presence can cause periodic episodes of inflammation, inducing and maintaining autoimmune uveitis.<sup>20,21</sup> Between clinical episodes, the number of organisms may decline enough that inflammation is not clinically detectable. This leads to a decline in the antibody level; when it falls below a certain level, the number of bacteria increases again, resulting in increased antibody production and damage to ocular structures. This theory is supported by the use of antimicrobial infusions into the vitreal cavity along with vitrectomy, which greatly reduces the frequency of episodes.<sup>21</sup>

Alternatively, T lymphocytes, the chief infiltrating cell type in the uveal tract, could reactivate when signaled.<sup>20</sup> Cell-mediated

## Key Facts

- Equine recurrent uveitis is also known as *moon blindness* or *periodic ophthalmia* because of its cyclical nature. It was once thought that the cycles of equine recurrent uveitis were related to the cycles of the moon.
- Leptospirosis is probably the most significant bacterial infection leading to recurrent uveitis in adult horses. Generally, clinical signs are not acute, but appear months to years after initial infection, and many infected horses never develop clinical signs.
- Equine recurrent uveitis is thought to be infectious or immune mediated in origin. Regardless of the pathogenesis, cell-mediated immunity plays the most important role in mounting an immune response.
- A genetic predisposition to equine recurrent uveitis has been identified in Appaloosas, of which those with a “leopard” coat color pattern seem to be affected more severely than those with other coat patterns.

immunity to uveal, corneal, and retinal antigens has been demonstrated in horses with equine recurrent uveitis. This theory proposes the following mechanism: If the causative organisms are cleared, systemic reexposure to the original antigen or exposure to a self-protein similar to the original antigen (molecular mimicry) may signal reactivation of the T cell and, therefore, inflammation.<sup>20</sup> In leptospiral-induced uveitis, the possibility that the organism is no longer present suggests that autoimmunity has occurred. Once the organisms are cleared, inflammation tends to subside as antiinflammatory cells take over, leading to a clinically quiescent period.<sup>21</sup> Reexposure to leptospira or molecular mimicry between leptospiral DNA fragments and the equine cornea, uvea, or retina reactivates the T cells. This theory is supported by the responsiveness of

equine recurrent uveitis to immunosuppressive therapy.<sup>20</sup>

Equine leukocyte antigen (ELA) typing has been used to determine whether individual horses are susceptible to developing equine recurrent uveitis, as it has been shown that humans with specific human leukocyte antigen haplotypes have increased susceptibility to autoimmune forms of uveitis.<sup>22</sup> A population of German Warmblood horses was used to evaluate MHC class I and class II alleles.<sup>22</sup> One particular allele, the MHC class I ELA-A9 haplotype, was present in almost half the horses with uveitis but was not found in any of the control horses. This association is important because the genes of the MHC/ELA regulate the inflammatory response and influence susceptibility to various diseases, particularly autoimmune diseases. The identified association between equine MHC class I ELAs and equine recurrent uveitis emphasizes the significance of the role of impaired immune function in this disease.<sup>22</sup>

In the United States, Appaloosas are eight times more likely to develop uveitis and nearly four times more likely to develop blindness due to equine recurrent uveitis compared with other breeds, which suggests a link between uveitis and genetic factors in horses.<sup>23</sup> Appaloosas with uveitis have a susceptibility allele in the MHC/ELA gene region, predisposing them to recurrent

uveitis.<sup>24</sup> Coat color microsatellite markers on chromosomes 1 and 21 are also associated with equine recurrent uveitis.<sup>25</sup> In particular, the allele responsible for the “leopard” coat pattern of Appaloosas is located on chromosome 1. Homozygotes have more “leopard complex” compared with heterozygotes, which have more base color and fewer spots; this corresponds to the clinical impression that leopard-coated Appaloosas are more likely to develop uveitis. In human studies, a link between uveitis and melanocytes has been suggested; therefore, it has been suggested that the lack of melanin in horses, particularly in Appaloosas, may predispose them to equine recurrent uveitis.<sup>24</sup>

## References

1. Deeg CA, Kaspers B, Gerhards H, et al. Immune responses to retinal autoantigens and peptides in equine recurrent uveitis. *Invest Ophthalmol Vis Sci* 2001;42(2):393-398.
2. Gerard MP. Infections of the head and ocular structures in the horse. *Vet Clin North Am Equine Pract* 2006;22(2):616-620.
3. Dwyer AE, Gilger BC. Equine recurrent uveitis. In: Gilger BC, ed. *Equine Ophthalmology*. Philadelphia: Elsevier; 2005:285-322.
4. Schwink KL. Equine uveitis. *Vet Clin North Am Equine Pract* 1992;8(3):557-574.
5. Gilger BC, Michau TM. Equine recurrent uveitis: new methods of management. *Vet Clin North Am Equine Pract* 2004;20(2):417-427.
6. Romeike A, Brugmann M, Drommer W. Immunohistochemical studies in equine recurrent uveitis. *Vet Pathol* 1998;35(6):515-526.
7. Deeg CA, Thurau R, Gerhards H, et al. Uveitis in horses induced by interphotoreceptor retinoid-binding protein is similar to the spontaneous disease. *Eur J Immunol* 2002;32:2598-2606.
8. Deeg CA. Ocular immunology in equine recurrent uveitis. *Vet Ophthalmol* 2008;11(suppl 1):61-65.
9. Deeg CA, Ehrenhofer M, Thurau SR, et al. Immunopathology of recurrent uveitis in spontaneously diseased horses. *Exp Eye Res* 2002;75:127-133.
10. Davidson MG. Equine ophthalmology. In: Gelatt KN, ed. *Veterinary Ophthalmology*. 2nd ed. Philadelphia: Lea & Febiger; 1991:596.
11. Bharti AR, Nally JE, Ricaridi JN, et al. Leptospirosis: a zoonotic disease of global importance. *Lancet Infect Dis* 2003;3(12):757-771.
12. Roberts SJ, York CJ, Robinson JW. An outbreak of leptospirosis in horses on a small farm. *JAVMA* 1952;121:237-342.
13. Wollanke B, Rohrbach BW, Gerhards H. Serum and vitreous humor antibody titers in and isolation of *Leptospira interrogans* from horses with recurrent uveitis. *JAVMA* 2001;219(6):795-800.
14. Davidson MG, Nasisse MP, Roberts SM. Immunodiagnosis of leptospiral uveitis in two horses. *Equine Vet J* 1987;19(2):155-157.
15. Dwyer AE, Crockett RS, Kalsow CM. Association of leptospiral seroreactivity and breed with uveitis and blindness in horses: 372 cases (1986-1993). *JAVMA* 1995;207(10):1327-1331.
16. Faber NA, Crawford M, LeFebvre RB, et al. Detection of *Leptospira* spp in the aqueous humor of horses with naturally acquired recurrent uveitis. *J Clin Microbiol* 2000;38(7):2721-2723.
17. Hartskeerl RA, Goris MG, Brem S, et al. Classification of *Leptospira* from the eyes of horses suffering from recurrent uveitis. *J Vet Med* 2004;51:110-115.
18. Brandes K, Wollanke B, Niedermaier G, et al. Recurrent uveitis in horses: vitreal examinations with ultrastructural detection of leptospire. *J Vet Med* 2007;54:270-275.
19. Pearce JW, Galle LE, Kleiboeker SB, et al. Detection of *Leptospira interrogans* DNA and antigen in fixed equine eyes affected with end-stage equine recurrent uveitis. *J Vet Diagn Invest* 2007;19(6):686-690.
20. Dwyer AE, Gilger BC, Kalsow CM. Equine recurrent uveitis. In: Gilger BC, ed. *Equine Ophthalmology*. Philadelphia: WB Saunders; 2005:285-322.
21. Miller PE. Uvea. In: Maggs DS, Miller PE, Ofri R, ed. *Slatter's Fundamentals of Veterinary Ophthalmology*. 4th ed. Philadelphia: WB Saunders; 2008:218.
22. Deeg CA, Marti E, Gaillard C, Kaspers B. Equine recurrent uveitis is strongly associated with the MHC class I haplotype ELA-A9. *Equine Vet J* 2004;36(1):73-75.
23. Dwyer AE, Crockett RS, Kalsow CM. Association of leptospiral seroreactivity and

breed with uveitis and blindness in horses: 372 cases. *JAVMA* 1995;207:1327-1331.

24. Brooks DE, Matthews AG. Equine ophthalmology. In: Gelatt KN, ed. *Veterinary Ophthalmology*. 4th ed. Ames, IA: Blackwell Publishing; 2007:1245-1246.

25. Rutherford MS, Kaese H, Hendrickson JA, et al. Equine recurrent uveitis association with the major histocompatibility complex. *Proc Plant Anim Genome Conf* 2008.



3 CE Credits

This article qualifies for 3 contact hours of continuing education credit from the Auburn University College of Veterinary Medicine. CE tests must be taken online at [Vetlearn.com](http://Vetlearn.com); test results and CE certificates are available immediately. Those who wish to apply this credit to fulfill state relicensure requirements should consult their respective state authorities regarding the applicability of this program.

**1. Which factor is typically not used to classify equine recurrent uveitis?**

- a. age of horse
- b. stage
- c. anatomic location
- d. clinical appearance

**2. Which clinical sign is not an acute change during the active inflammatory phase of equine recurrent uveitis?**

- a. blepharospasm
- b. aqueous flare
- c. cataract
- d. conjunctival hyperemia

**3. Uveitis has been associated with**

- a. herpesvirus and equine infectious anemia virus.
- b. influenza virus and equine infectious anemia virus.
- c. herpesvirus and influenza virus.
- d. all of the above

**4. Which of the following is not a parasitic cause of uveitis?**

- a. *O. cervicalis*
- b. *Culicoides* spp
- c. *T. gondii*
- d. none of the above

**5. In the United States, the leptospire most commonly isolated in vitreal and aqueous titers is**

- a. *L. interrogans* serovar *pomona*.
- b. *L. kirschneri* serovar *grippotyphosa*.
- c. *L. borgpetersenii* serovar *ballum*.
- d. *L. interrogans* serovar *canicola*.

**6. Acute clinical signs of leptospirosis are rare in horses; however, \_\_\_\_\_ has been documented.**

- a. lameness
- b. ataxia
- c. bruxism
- d. abortion

**7. \_\_\_\_\_ is not a reliable method of diagnosing ocular leptospiral infection.**

- a. Microscopic agglutination testing
- b. Bacterial culture
- c. Serology
- d. Polymerase chain reaction testing

**8. Which intraocular structure can act as an accessory lymph node?**

- a. the uvea
- b. the retina
- c. the lens
- d. the optic disk

**9. \_\_\_\_\_ immunity seems to play the most important role in uveitis.**

- a. Humoral
- b. Cell-mediated
- c. Active
- d. Herd

**10. Which equine breed has the highest predilection for developing equine recurrent uveitis in the United States?**

- a. Arabian
- b. Thoroughbred
- c. Warmblood
- d. Appaloosa